

Common Knee Problems

Introduction

The knee is the second most commonly injured joint in the body after the ankle. It is also a common joint to develop degenerative conditions such as arthritis, with the population at risk of developing arthritis in the knee being about 1% of the population. As the population ages, the number of individuals with symptomatic arthritis is also going to rise.

Anatomy / Physiology

The knee joint is the largest synovial joint in the body. It is made up by 3 bones comprising the distal femur and proximal tibia, which make up the major articulation of the knee joint. There is a smaller, but equally important articulation between the femoral trochlear and the patella (a sesamoid bone within the quadriceps tendon), which makes up the patellofemoral articulation (Figure 1).

The function of the knee joint is made possible due to various static constraints, such as the articular cartilage menisci ligaments and bones combined with the dynamic functions of the surrounding muscles and tendons (Figure 1).

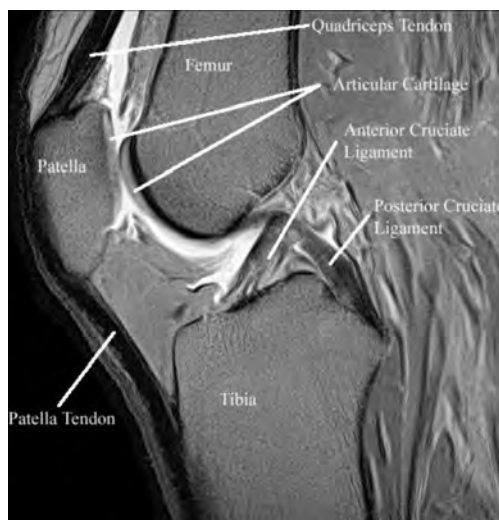


Figure 1 – Sagittal MRI image showing anatomy of the knee. (ortho pics – knee pics)

Any of these structures can be injured or become deranged to adversely affect the function of the knee joint and create the commonly experienced symptoms of pain and swelling, locking, giving way and so forth.

The menisci have a unique role in the knee joint to increase the surface area of the articulation between the femur and tibia and therefore reduce force transmitted from the femur to the tibia due to the innate structure of menisci. The particular anatomy of the menisci that allow this are the collagen fibres that run circumferentially from the anterior horn to the posterior horn (Figure 2). The continuity of these fibres produces the biomechanical features of so called “hoop stresses”. This is where a force acting to compress the meniscus is transmitted into a force which is then dissipated through the circumferential fibres around the meniscus and outwards. This function can only occur if the fibres are in continuity and the commonest way that this continuity fails is when menisci tear. This tearing leads to disruption in the hoop stresses, which means the force can no longer be dissipated in that part of the meniscus. The force, therefore, increases in that area between the femur and the tibia. Articular cartilage is not designed to constantly take high force loading, which if occurs, will result in the articular cartilage failing, breaking down and ultimately the articular cartilage will be lost to form an osteoarthritic lesion.

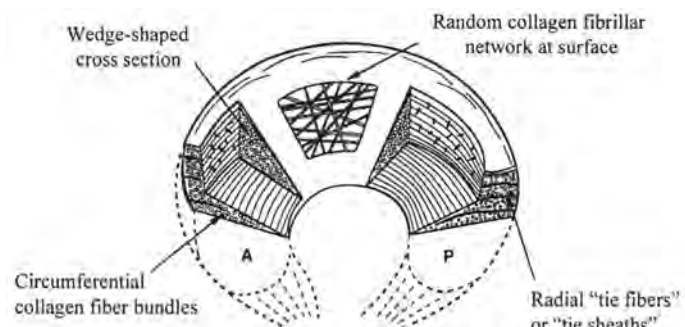


Figure 2: Anatomy of meniscus. (ortho pics – knee pics – knee misc)

This failure of the meniscus in force transmission will occur as soon as the meniscus tears and it is not so much the removal of the meniscus that causes the problem, but the tearing itself. Once the meniscus

is torn, it has, in essence, functionally been removed from the knee causing increasing loading in that part of the knee (Figure 3).

There is an innate relationship between anatomy and physiology, as is demonstrated by the above example in the knee.

The patellofemoral joint will take up to 8-10 times an individual's body weight when the individual undertakes activity such as going up and down stairs, or running and jumping. It is, therefore, not difficult to see why the patellofemoral joint commonly is a source of degeneration and symptoms.

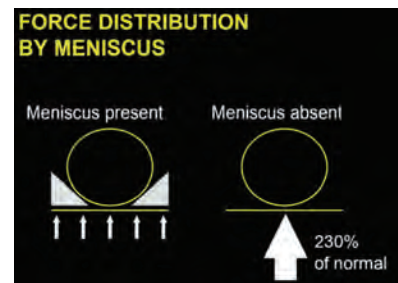


Figure 3: Effect of meniscal tears / removal on force transmission in the knee. (ortho pics – meniscal tears)

Clinical Knee Conditions

Knee pathology can generally be divided into traumatic and degenerative.

The traumatic group can be subdivided into acute traumatic episodes, such as fractures, dislocations, ligament ruptures and the chronic trauma or overuse group. The overuse group would commonly be conditions such as tendonitis or even meniscal tears.

The degenerative group may occur as a result of previous acute overuse trauma with the final common pathway being osteoarthritic changes within the joint or chronic degenerative changes occurring within the joint.

Before considering individual pathology, it is prudent to comment on diagnosis.

As we have all been taught during our medical school careers, 80% of the diagnosis of any condition is made from the history with a further 10% or so being confirmed on the examination. The same applies to diagnosing common knee problems and therefore an innate part of treating our patients is the ability to obtain a good history in order to provide a diagnosis or at least a differential diagnosis.

In many conditions, the history is not difficult to obtain. For example, in individuals with progressive osteoarthritis, the history will be a progressive increase in pain and reduction in function, together with complaints of swelling, sleep disturbance, limitation of walking and there may be even mechanical symptoms such as locking, catching and giving way. A little bit more challenging is the diagnosis in knee injuries. If an individual is questioned closely on facets of their history it is not uncommon to be able to diagnose their traumatic pathology.

If one is seeing an individual with a knee injury, a few minutes going in to their mechanism of injury can be invaluable diagnostically. The sort of factors to consider include enquiring whether the individual's injured knee had the corresponding foot planted on the ground at the time of their injury, or off the ground. Most serious knee injuries tend to occur when the individual's foot is on the ground and the weight is on their leg.

It is important to enquire whether their knee sustained a direct blow and, if so, from which side. This is a common mechanism for tearing, primarily, the collateral ligaments depending upon the side of injury. If the leg is planted on the ground and the individual is struck from the lateral side, it will commonly be a medial collateral ligament injury and vice versa.

An individual who provides a history along the lines that they were running, suddenly planting their foot to change direction, felt a click or a pop, fell to the ground, the knee swelled up and they were unable to continue playing, is a classical history for an anterior cruciate ligament (ACL) tear. Differential diagnoses would include an acute patella dislocation.

Following a knee injury, one should enquire whether the knee swelled and if so, how quickly. If swelling occurs within seconds to minutes of the knee injury occurring, this would indicate bleeding into the joint (hemarthrosis). 80-85% of acute hemarthrosis with an appropriate history should be considered to be a tear of the anterior cruciate ligament until proved otherwise. Other causes for acute hemarthrosis would be patella dislocations, large meniscal tears or intra-articular fractures.

Injuries occurring when an individual is jumping, landing, or changing directions, are classically an ACL tear or potentially a patella dislocation.

If an individual falls and lands on their knee, enquiry of whether the foot at the time of the landing was dorsiflexed or plantar flexed can provide some diagnostic information. Generally, if the foot is plantar flexed, the individual lands on their tibial tuberosity, which if injuring the knee will cause a tear of the posterior cruciate ligament (Figure 11). If the foot is dorsiflexed the individual will usually land on the patella, sustaining an injury to the patellofemoral joint.



Knee Pathology Bursas

There are many bursas around the knee (Figure 4). The common bursas seen include the pre-patellar bursa (housemaids knee) (Figure 5) and infrapatellar bursa (clergyman's knee). The diagnosis is usually self-evident from the swelling. The onset can be traumatic or of gradual onset. With the anterior knee bursas, there is usually history of repetitive kneeling.

The treatment is generally similar with initially rest, ice and anti-inflammatories. Aspiration and injection of steroid can be considered in a clean environment so as to minimise the potential risk of infection. The final option of treatment is surgical removal, which may be done open or arthroscopic. The open route is a more common. It is however important the patient is aware they will be swapping a lump for a scar. Sometimes the scars can be as troublesome as the bursas / lump that were present previously, especially in scenarios where the individual is going to be kneeling. With all treatment methods there is a risk of recurrence, but this is obviously lowest with surgical removal. Generally, if the bursa does not bother the individual then they can be simply observed.

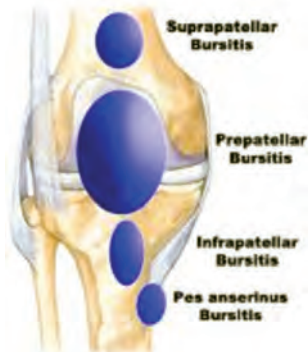

Figure 4: Bursas around the knee (ortho pics - knee misc)

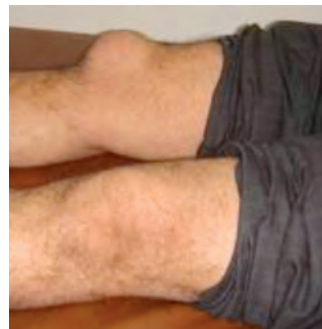

Figure 5: Pre patella bursa right knee (housemaid's knee) (ortho pics - knee misc)

Meniscal Tears

Meniscal tears are very common pathology, encountered by GPs as well as Orthopaedic Surgeons. Occasionally a history of acute trauma is provided with an individual either twisting or stumbling on their knee. More often than not, with degenerative meniscal tears, there is no specific history of injury or overuse. Commonly an individual will complain that they woke up one morning and the knee was painful and swollen and they had difficulty walking. Pain is usually localised to the side of the meniscal tear, either medial or lateral. Generally their symptoms will gradually get better and could be treated expectantly with ice, anti-inflammatories, rest and elevation.

Meniscal tears generally have no capacity to heal themselves. The reason being there is no adequate blood supply running through them (Figure 6). Therefore, if the tear does not heal, although the symptoms can improve, generally will tend to recur when an individual aggravates their knee. The aggravation commonly will occur with activities involving twisting, kneeling or squatting, as these all put rotational forces on the meniscus generating pain and swelling. Therefore, while individual's symptoms can improve, with meniscal tears symptoms tend to recur with the frequency of recurrence becoming more so as time goes on.

It should also be borne in mind that not all meniscal tears are symptomatic. Indeed, it is estimated that about 30% over the age of 40, with no knee symptoms, will be found to have asymptomatic meniscal tears on an MRI scan. Therefore, not all meniscal tears require treatment unless symptomatic.

The key examination findings of meniscal tears are joint line tenderness over the medial or lateral aspect of the knee. It is generally considered that meniscal joint line tenderness tends to occur towards the posterior half of the meniscus, either medially or laterally (Figure 7). The joint line tenderness tends to be maximal at one point.

There are a number of meniscal tests that are described (Figure 8). They all have the common feature of trying to increase an individual's pain by trapping the torn meniscus. Examples include McMurray's test. The key to these tests is to ensure that the patient's knee is flexed deeply and then rotated into different positions of flexion or extension. The key, however, is the deep

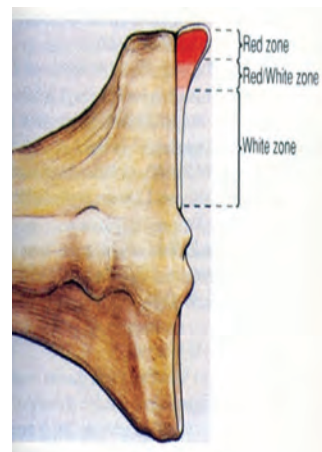


Figure 6: Blood supply of meniscus. There is some blood at the capsular margin of the meniscus (red zone) but this diminishes towards the free edge of the meniscus (white zone). (ortho pics - meniscal tears)

flexion, as this is the position at which the meniscus gets trapped. A positive test would be reproduction of pain over the site of maximal tenderness, occasionally with a click, although the click is not mandatory.

The diagnosis can be made on the history and examination in the vast majority of patients with meniscal tears. Indeed, studies have been found to show that experienced clinicians are more accurate at diagnosing meniscal tears than MRI scans. It also should be borne in mind that MRI scans are not 100% sensitive at picking up meniscal tears and can miss up to 10-15% of meniscal tears. However, if the diagnosis is suspected, an MRI scan would be the investigation of choice so as to illustrate the meniscal tear (Figure 8)

There are many types of meniscal tear (Figure 9). The key principal in treating meniscal tears is to preserve as much normal meniscal tissue as possible for the reasons outlined in the previous discussion, ie to try to keep loading forces down in the knee (Figure 3).

Initial treatment options include conservative treatments. Consideration may also be given to a steroid injection intra-articularly, which will reduce an individual's symptoms of pain and swelling. It is usually, however, a temporary phenomenon and sooner or later the symptoms tend to recur once the steroid wears out.

Ultimately, for symptomatic meniscal tears, the treatment tends to be surgical with an arthroscopic partial meniscectomy, leaving behind as much normal tissue as possible. If it is an acute meniscal injury, which appears traumatic on imaging or at the time of arthroscopy and is peripheral and close to the capsular margin (which has a blood supply) (Figure 6), consideration should be given to meniscal repair. The reason being, that if the meniscus is repaired early on, the tear is non-degenerate and goes on to heal, it is possible to return normal meniscal function to the meniscus.

Generally, medial meniscal tears are much more common than lateral meniscal tears. The reason being, that most individuals have their body weight axis running through the medial compartment, which will therefore load and more likely injure the medial meniscus.

Occasionally, in young individuals, a large piece of meniscus has to be removed, such as in irreparable bucket handle meniscal tears. In this group consideration can be given to meniscal transplantation to try and preserve knee function.

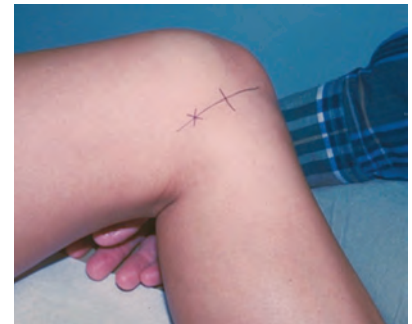

Figure 7: Medial side of Left knee. Clinically, meniscal tear pain on palpation is usually at point X or posterior to the vertical line, which is the half way point of the joint line. Pain or tenderness anterior to the line is not usually meniscal in origin.

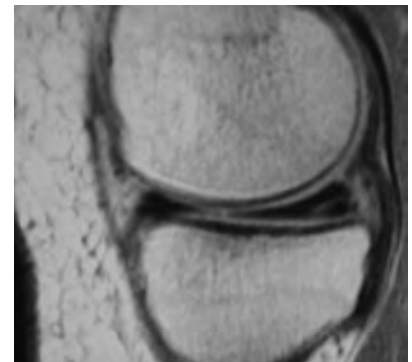


Figure 8: Meniscal tear seen on an MRI scan. The tear is a white line through the black triangle representing the meniscus. (ortho pics - meniscal tears)

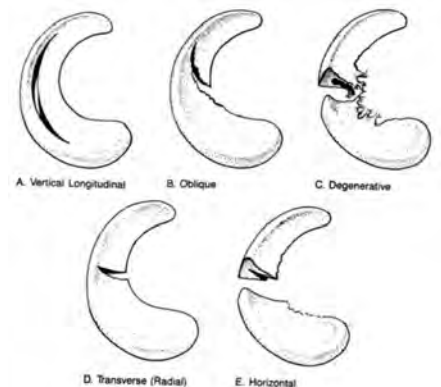


Figure 9: Different types of meniscal tears. (ortho pics - meniscal tears)

Common Knee Problems

(continued)

Anterior Cruciate Ligament Tears (ACL)

The ACL is a commonly injured ligament in the sporting environment but can also occur in slips and falls. ACL tears are a major traumatic injury to the knee, as significant forces have to be imparted to the knee joint to tear the ligament. Consequences of an ACL tear are also significant to the extent that an individual who tears their ACL has a ten-fold increase in their risk of arthritis development within their knee.

The diagnosis can be made through a detailed history. The classical history of an ACL tear is an individual running that suddenly stops or reacts, to change direction, the knee gives way, they may hear a pop, they fall to the ground, the knee swells up immediately and they are unable to play on. Given this history, an ACL tear should be assumed until proven otherwise.

In the acute examination situation the knee will be markedly swollen with very little movement and will be painful. The initial treatment is to ice the knee, rest the knee, elevate it, and to take anti-inflammatories and painkillers, together with physiotherapy. The aim is to reduce swelling and start to increase the range of motion. If there is any concern regarding the mechanism of injury, x-rays should be arranged to exclude fractures. Within a couple of weeks of this type of treatment, the knee can be re-examined once it has settled somewhat. The classical findings on examining an individual with an ACL tear are laxity of the anterior cruciate ligament, which can be diagnosed on a Lachmann's test or an anterior drawer (both these tests assess how much anterior movement there is of the Tibia on the Femur as the Tibia is pulled forward. The injured side should be compared to the normal knee). If there is any concern or suspicion of a torn ACL, they can be referred to the Orthopaedic Surgeons for further assessment and treatment. An MRI scan can be arranged to show the tear (Figure 10).

The function of the anterior cruciate ligament is to provide rotational stability of the knee. Once the ACL is completely torn, it does not have the ability to heal in general terms. Individuals with ACL tears lack rotational control of their knee, such that if they plant their leg to change direction the knee will usually give way. This may occur if they return back to sports, or can occur in their everyday activities. The majority of individuals with ACL tears usually will require an ACL reconstruction.

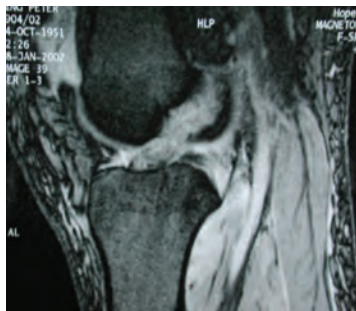


Figure 10: MRI scan of the knee showing a tear of the ACL. The normal ACL is a black structure on an MRI scan, whereas on this scan it is all white (bleeding) with no fibres seen running through it. (ortho pics - ACLuk)

Posterior Cruciate Ligament (PCL) Injuries

The PCL is much less commonly injured, compared to the ACL. The diagnosis is not uncommonly missed. The PCL can and usually does heal. A PCL tear is not as disabling as an ACL tear. Most individuals with isolated PCL tears do not require surgical treatment.

The examination can confirm the diagnosis of PCL injuries, although the examination findings can be subtle, compared to an ACL tear. The test that is classically used is a posterior drawer. In this test, posterior translation of the tibia on the femur is assessed at 90 degrees of knee flexion.

Comparison should always be made to the normal knee to get an idea of what is normal for the individual.

The common mechanism for tearing the PCL is a fall on to the front of a bent knee (Figure 11), or the bent knee being struck by an object such as a dashboard in a road traffic accident. They can occasionally occur in a sporting environment with rotational mechanisms. Typically, individuals with PCL tears will complain of posterior knee pain with only minor degrees of swelling.

The treatment for an acute PCL injury, of lower moderate grade, would be to splint the knee in extension for 4-6 weeks and prevent hyperextension. They would then be put through a physiotherapy rehabilitation programme. Individuals with healed PCL tears will commonly return back to all their normal activities, including high level sports.

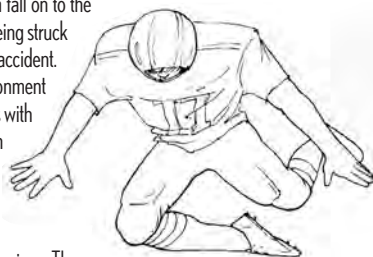

Figure 11: Fall on the front of the bent right knee with the foot plantar flexed can tear the PCL.

Collateral Ligament Injuries

Collateral ligament injuries usually occur from direct blows to the medial or lateral aspect of the knee or lower leg. They are usually isolated injuries but can occur in combination with the ACL or PCL, such as in sporting environments.

The usual examination findings are localised tenderness over the medial or lateral structures with laxity of the ligaments on varus or valgus stressing. The laxity should be compared to the normal knee, as some degree of laxity of the collaterals is present in everyone's knees normally. In low grade injuries, laxity is present at about 30° of knee flexion. In high grade injuries (grade 3), laxity is present with the knee in full extension which would indicate that the knee capsule is also injured. In this latter situation, the individual would be best served being referred to the Orthopaedic Services.

Medial collateral ligament injuries will usually heal in all grade of injury. The treatment would be to initially immobilise the knee in a cast or brace, followed by a graduated physiotherapy-based programme. Surgical treatment to acute medial collateral ligament injuries is very uncommon in isolation.

Lateral side injuries, however, are different and commonly may not heal. The lateral side of the knee has 6 major anatomical structures which contribute to the stability of the knee. While individual injuries to one or two of these structures can be tolerated by the knee, if three or more are injured usually surgical treatment will be required.

With lateral side injuries, these commonly occur in conjunction with ACL or PCL tears. With acute lateral side ligament injuries, the ideal option is surgical repair within the first 10-14 days. Therefore, if lateral sided injuries are suspected, it is recommended to refer the individuals acutely to the Orthopaedic Services.

Osteoarthritis of the knee (localised and generalised)

Osteoarthritis is a very common and increasing common condition seen by GPs and Orthopaedic Surgeons. It is estimated that 1% of the population will develop arthritis in the knee requiring treatment. As the population ages, the number of individuals with symptomatic arthritis will also increase.

Arthritic symptoms have a progressive onset usually, although acute flare-ups can occur. Arthritis can occur constitutionally, but more and more post-traumatic arthritis is now being encountered in younger individuals. This can occur following intra-articular fractures, major ligament injuries to the knee, such as the anterior cruciate ligament, or following sub-total meniscectomies in meniscal tears.

The patient will complain of pain, which may be localised to one compartment, but more often is generalised. They will commonly complain of swelling, reduced walking distance, and as the disease progresses, may also develop rest pain and night pain. They can also develop deformities such as the more common, varus (bow legged) (Figure 12) and less common valgus (knock kneed) deformities. They will also lose the ability to fully straighten their knee and develop fixed flexion contractures, which also can affect an individual's ability to walk.

These features are also picked up on when examined, with reduced range of motion and fixed deformities, together with swelling. This diagnosis can be confirmed radiologically on plain x-rays (Figure 13). In the earlier stages, or in individual's with localised areas of arthritis (chondral or osteochondral defects), MRI scanning can be diagnostic.

The treatment is dependent upon the distribution and severity of the arthritis. In young individuals who sustain significant traumatic injuries to their knee, such as patella dislocations or ligament injuries, they can develop localised areas of traumatic arthritis (chondral defects) (Figure 14). This can also occur in developmental conditions such as osteochondritis desiccata. In these conditions, in young individuals, the goal of treatment is to try and preserve or regenerate articular cartilage.

The treatment options will include procedures such as microfracture (Figure 15), cartilage regeneration techniques, or articular cartilage transplantation (Figure 16). These techniques are undertaken by specialist knee surgeons and have good success rates, having been undertaken for over 15 years now. Individuals with these pathologies require specialist referral.

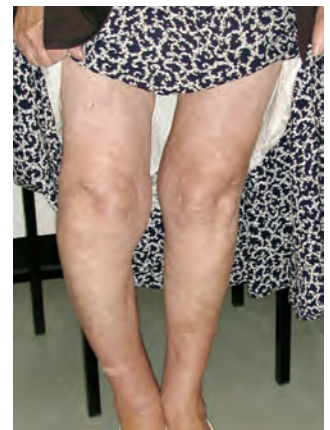

Figure 12: Varus (bow legged) deformity of advanced knee arthritis Right knee. (Kneedoc pics - Bowlegged)

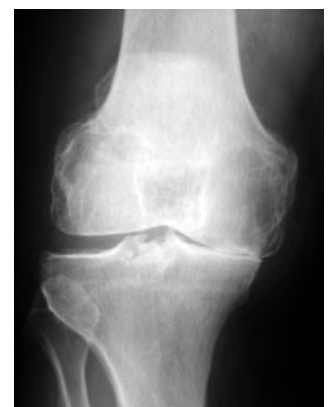

Figure 13: Advanced medial compartment knee OA Right knee. (Ortho pics - TKR - Case 4A)

Figure 14: Traumatic chondral defect of medial femoral condyle. (ortho pics - osteochondral - acid big)

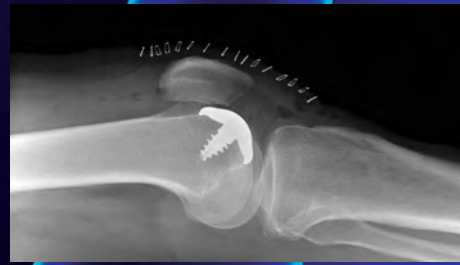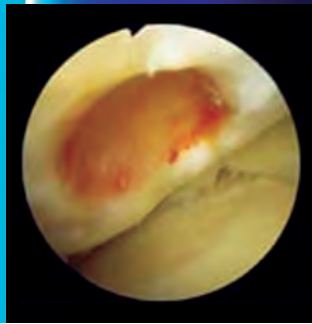


Figure 18: Xray of patellofemoral replacement (isolated trochlear replacement).

In more advanced localised arthritis, which may for example involve both sides of the joint such as the femur and tibia or the patella and the femur, cartilage transplantation options are not as effective and may be contraindicated. In these scenarios one would consider localised arthroplasty options, such as unicompartmental knee replacements (figure 17) or isolated patellofemoral replacement (figure 18).

The role of arthroscopic procedures in arthritis is more controversial. There is a place for it, but generally the days of lavage and washout of arthritic joints has gone, as there is good evidence to show that this does not work and may in fact make the individual worse. Patients, however, with localised mechanical findings, such as joint line tenderness with locking, catching and giving way, may benefit from arthroscopic procedures to debride their meniscal tears and remove any loose fragments or loose bodies. Arthroscopies in this group of individuals can be quite successful.

In more widespread generalised arthritis, ultimate treatment is total knee replacement surgery. However, in general terms, the aim would be to try and delay arthroplasty surgery for as long as possible, as the average knee replacement has a survivorship of about 10-15 years and would therefore mean in younger individuals, it would require revising. This requirement to aim to delay arthroplasty surgery has, however, to be weighed-up against an individual's quality of life. For example, a 50 year old patient with an arthritic knee and significant intrusion of their quality of life may warrant consideration of total knee replacement to improve their quality of life if it is accepted that they are likely to require 1 or more revision knee replacements during their life time.

Other options to treat knee arthritis include osteotomies. All of the options such as arthroscopic procedures, cartilage regeneration, osteotomies and even, potentially, unicompartmental replacements, are designed to try and delay the potential requirement of a total knee replacement.

Technology has advanced with total knee replacements surgery, as in other aspects of medicine. The aim of knee replacement surgery is to try to provide a pain-free, functional knee replacement with as long a survivorship as possible, so as to minimise the risk of revision. One of the key factors in delaying revision is having a well aligned knee replacement. Technology can be used to aid with this. Personalised knee replacements are now available and frequently used in my practice.

Personalised knee replacement involves the individual having a preoperative MRI or CT scan in order to 3-dimensionally model their knee anatomy. From this model, computer generated cutting blocks are designed to reproduce anatomical alignments (Figure 19). These blocks are then sent to the surgeon in order to undertake the knee replacement, with the blocks being personalised to the patient's anatomy and corrections required.

Personalised knee replacements also have additional benefits, such as allowing minimal incision surgery, which reduces pain, swelling, and improves recovery rates, thus reducing length of stay. It also does not require penetration of the intramedullary canal of the knee, therefore, reducing fat emboli and its consequence risks to the patient (Figure 20).

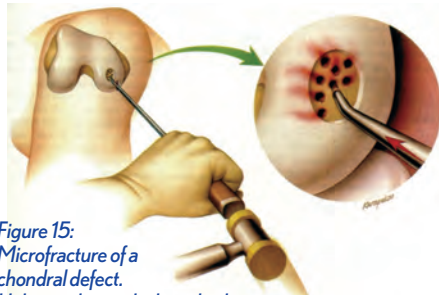


Figure 15: Microfracture of a chondral defect. Holes made into the bony bed of the lesion, to stimulate release of stem cells, which will transform into cartilage. (ortho pics - osteochon leis)

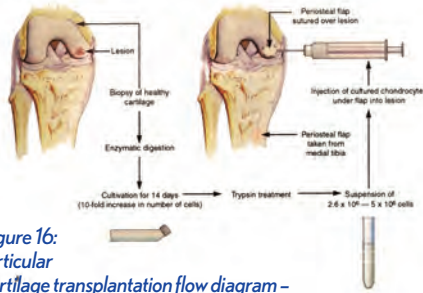


Figure 16: Articular cartilage transplantation flow diagram - Two stage undertaking. (ortho pics - osteochon leis)

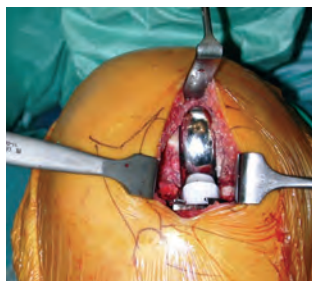

Figure 17: Unicompartmental knee replacement of medial compartment through minimally invasive technique. (ortho pics - uni - case 2b op)

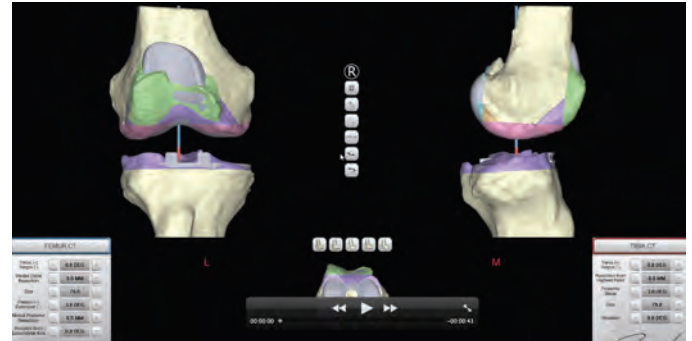


Figure 19: Personalised Knee replacement computerised model generated from MRI or CT scan of patient's knee. The computerised model can be adjusted by the surgeon to meet appropriate criteria. (clinical - signature)

Personalised knee replacements are more expensive than standardised knee replacements and are commonly not funded by the NHS. However, private insurance companies do fund this surgical technique.

Technopathies

Tendinopathies are an overuse injury. Their frequency is increasing as the population is becoming more active and undertaking more sports. Around the knee tendinopathies can occur in the patellar tendon, the quadriceps tendon, the hamstring tendons and the iliotibial band.

The patient's history is usually one of gradual onset of pain in the particular tendon. Initially, it will tend to occur after the individual has played their sport or exercise. As the tendinopathy worsens, it tends to intrude into the individual's sport and so may stop them playing or exercising. As it becomes more severe, the pain can also occur at rest.

Tendinopathic tendons are at risk of rupture.

Tendinopathies tend to occur in individual's who undertake regular impact-loading sport that involves running and jumping.

The typical examination finding is usually no swelling in the knee with an essentially full range of motion. The individual usually, however, has fairly localised point tenderness over the particular involved tendon.

The treatment for tendinopathies is usually non-surgical. Initially, the individual will have to stop their triggering sport. They may be able to continue non-impacting loading exercise such as swimming and riding a bike, as long as it does not cause pain in the tendons. Physiotherapy modalities can be used, including shock wave treatment to try and break down the tendinopathic process within the tendon and increase the healing rate. Certain types of strengthening processes can also be used, including eccentric strengthening.

Further non-interventional treatments are commonly used, which include dry needling, platelet rich plasma (PRP) injection, and autologous blood injection. The aim of these three treatments is to increase blood flow and growth hormones into the tendinopathic tissues so as to increase the healing rates. Ultimately, if the tendonitis does not respond, then the final treatment would be surgical excision of the tendinopathic segment.

Conclusion

The majority of knee problems can be diagnosed with a detailed history and a good examination. Specialised imaging, such as MRI scanning, is also commonly used as an adjunct to diagnosis.

Common knee conditions are discussed in this article, including management options.

For further information on treatment options, please visit www.thekneedoc.co.uk. For further information on knee sports injuries, please visit www.football4football.com/injuries.

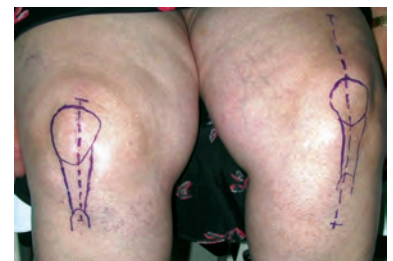

Figure 20: Minimally invasive incision in patient's right TKR performed by author, compared to routine incision in a standard TKR in patient's left knee. The minimally invasive procedure has a number of benefits of which cosmesis is actually the least important, but not for the patients.